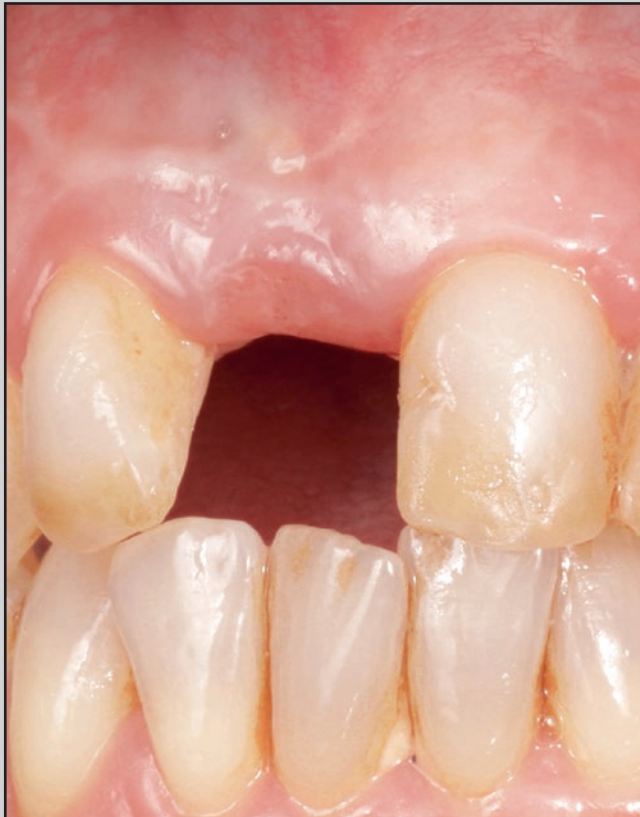
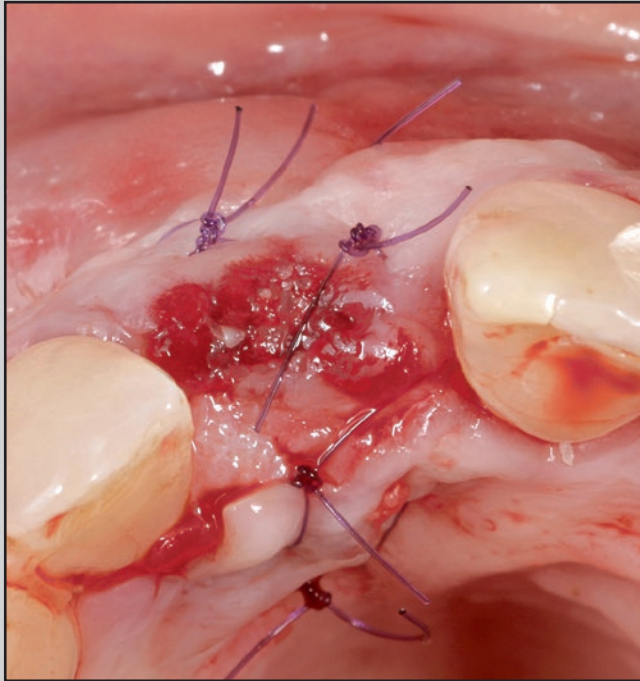
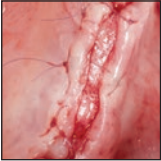Buccal Sliding Palatal Pedicle Flap Technique for Wound Closure After Ridge Augmentation



Snježana Pohl, MD, DMD¹
Maurice Salama, DDS²
Pantelis Petrakakis, DDS, DPH³

One standard approach for wound closure after ridge augmentation is coronal flap advancement. Coronal flap advancement results in displacement of the mucogingival junction and reduction of the vestibulum. In the maxilla, a buccal sliding palatal flap can be applied for primary wound closure after ridge augmentation. The dissected part of the palatal connective tissue is left exposed, thus eliminating or reducing the amount of the coronal flap advancement respectively and increasing the amount of keratinized gingiva. In combination with guided soft tissue augmentation, this flap design enables a three-dimensional peri-implant soft tissue augmentation. Int J Periodontics Restorative Dent 2020;40:741–747. doi: 10.11607/prd.4544

After tooth extraction, resorption of bundle bone will occur, which is in large part due to the physiologic healing process.¹ In order to create adequate conditions for implant treatment, augmentation procedures are required in many patient cases. Numerous techniques for hard tissue augmentation have been described in the literature. Primary wound healing is an important factor for success of the augmentation procedure and can be achieved by tension-free primary wound closure.² Passive closure of the soft tissue margins is a prerequisite for uneventful wound healing and ensures predictability of the desired treatment outcome.² One standard approach for primary closure is coronal advancement of the buccal flap. In order to advance the buccal flap coronally, a periosteal releasing incision is required.³ Hematoma, swelling, and discomfort are common clinical findings after a periosteal releasing incision, and coronal flap advancement often results in displacement of the mucogingival junction and reduction of the vestibulum. Due to these shortcomings, second-stage surgery will be necessary, comprising apical flap reposition and additional surgical measures for peri-implant soft tissue volume gain.⁴

In order to avoid or reduce the amount of buccal flap coronal ad-

¹Private practice, Rijeka; Department of Oral Medicine and Periodontology at University of Rijeka, Rijeka, Croatia.

²Department of Periodontics, University of Pennsylvania, Philadelphia, Pennsylvania; Medical College of Georgia, Augusta, Georgia; Private practice, Atlanta, Georgia, USA.

³Private practice, Duesseldorf, Germany.

Correspondence to: Dr Snježana Pohl, Department of Oral Medicine and Periodontology at University of Rijeka, Franje Čandeka 39, Rijeka 51000, Croatia. Email: snjezana.pohl@gmail.com

Submitted July 4, 2019; accepted October 6, 2019.

©2020 by Quintessence Publishing Co Inc.

vancement and to provide primary wound closure after bone augmentation in the posterior maxilla, Tinti and Parma-Benfenati introduced the palatal sliding flap technique in 1995.⁵ Another technique for covering the augmented area with a palatal sliding flap was presented by Fugazzotto.⁶ Palatal sliding flap comprises a preparation beginning with a horizontal palatal incision. It requires at least 4.0 mm soft tissue thickness in order to avoid flap perforation during flap dissection, and hence the palatal sliding flap is very technique-sensitive.

The buccal sliding palatal pedicle flap (BSPPF) technique represents a procedure that is less technique-sensitive, utilizing palatal connective tissue with pedicle periosteum from the buccal flap. Combined with guided soft tissue augmentation, the BSPPF technique helps to avoid or minimize the required amount of coronal flap displacement and enhances the peri-implant soft tissue volume at the same time.⁷

This flap design complies with the modified roll technique described by Scharf and Tarnow, which was mainly created for soft tissue augmentation with esthetic objectives.⁸ By means of BSPPF, the dissected palatal soft tissue is not rolled underneath the buccal flap, but is instead stretched over the ridge crest.

Merli described deployment of a buccal pedicle palatal flap at the time of implant exposure and application of healing abutments in order to cover the exposed ridge.⁹ In 2018, Linkevičius et al ascertained a significant mean gain of soft tissue

volume from 2.30 up to 3.65 by using 2.0-mm-high healing abutments at the time of implant placement. Thus, by creating space underneath the covering mucosal flap, soft tissue thickness was improved and bone loss could be reduced.¹⁰

This is consistent with a previous report by Salama et al,⁷ who termed this concept “guided soft tissue augmentation.”

As shown in both studies, guided soft tissue augmentation requires certain space for enhancement of the soft tissue volume in all three dimensions. Healing abutments scaffold and create space beneath the gingiva to promote formation of blood clots with a subsequent angiogenesis, enabling both formation of new bone and soft tissue augmentation.² Sufficient peri-implant soft tissue dimensions protect the underlying bone from resorption.¹¹

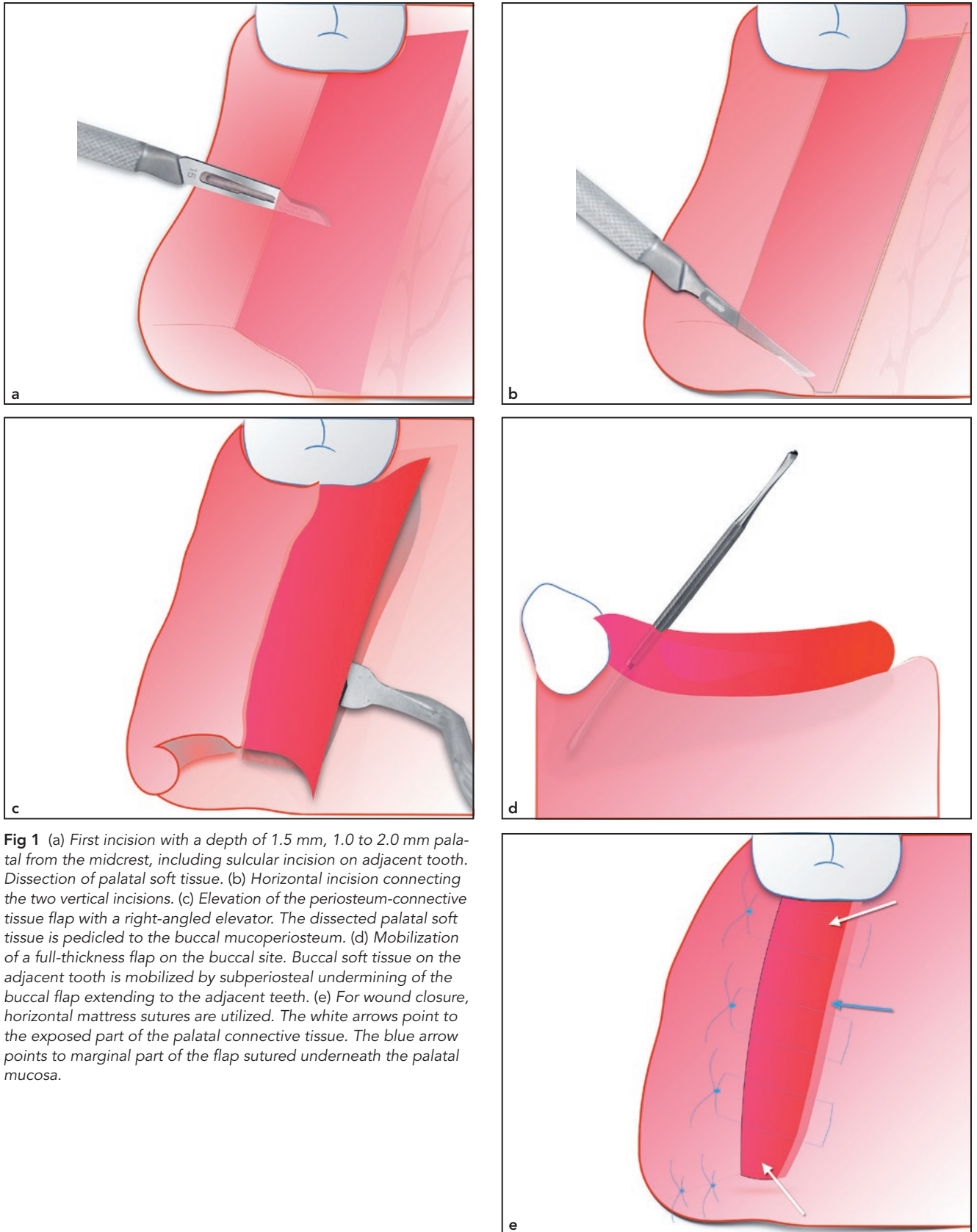
Materials and Methods

Surgical intervention begins with a 1.5-mm-deep palatal incision at a distance of 1.0 to 2.0 mm from the midcrest of the edentulous ridge, including a sulcular incision on the palatal site of the adjacent tooth (Fig 1a). Flap preparation of subepithelial connective tissue is performed towards the median raphe of the palate, ensuring maintenance of an adequate flap thickness (at least 1.5 mm) in order to reduce risk of sloughing of the overlying tissue (Fig 1a).

Dissection of subepithelial tissue extends 3.0 to 4.0 mm to the mesial and distal parts of the edentulous surgical site. Subsequently,

two vertical incisions—one each at the mesial and distal aspects—are performed at the palatal site up to the bone. The medial extension of the two incisions is connected by a third, horizontal incision (Fig 1b). Connective tissue flap and periosteum are released with a right-angled elevator from the palatal bone, beginning at the palatal horizontal incision and moving towards the buccal site until soft tissue is detached from the underlying bony surface (Fig 1c). Flap size is dictated by the shape of the palatal vault, which reflects the position of the greater palatine artery.¹² Measured from the cemento-enamel junction of the posterior maxillary teeth, the palatal artery is located at a mean distance of 7.0 mm in a flat palate, 12.0 mm in an average palate, and 17.0 mm in a high palate. These different ranges have to be taken into account during surgery in order to keep a safe distance between the most medial part of the incision and the neurovascular bundle of the palate.

The next step comprises preparation of the buccal mucoperiosteal flap. In cases where extensive horizontal ridge augmentation procedures are needed, vertical incisions at the buccal site and extending over the mucogingival junction are performed in order to avoid any compression of the augmented area. Vertical incisions are placed on a line angle distant to the surgical site on the adjacent tooth and at a distance of 5.0 to 6.0 mm from the edentulous area. In cases where only moderate flap advancement is required, the subperiosteal flap can be mobilized without an open-flap



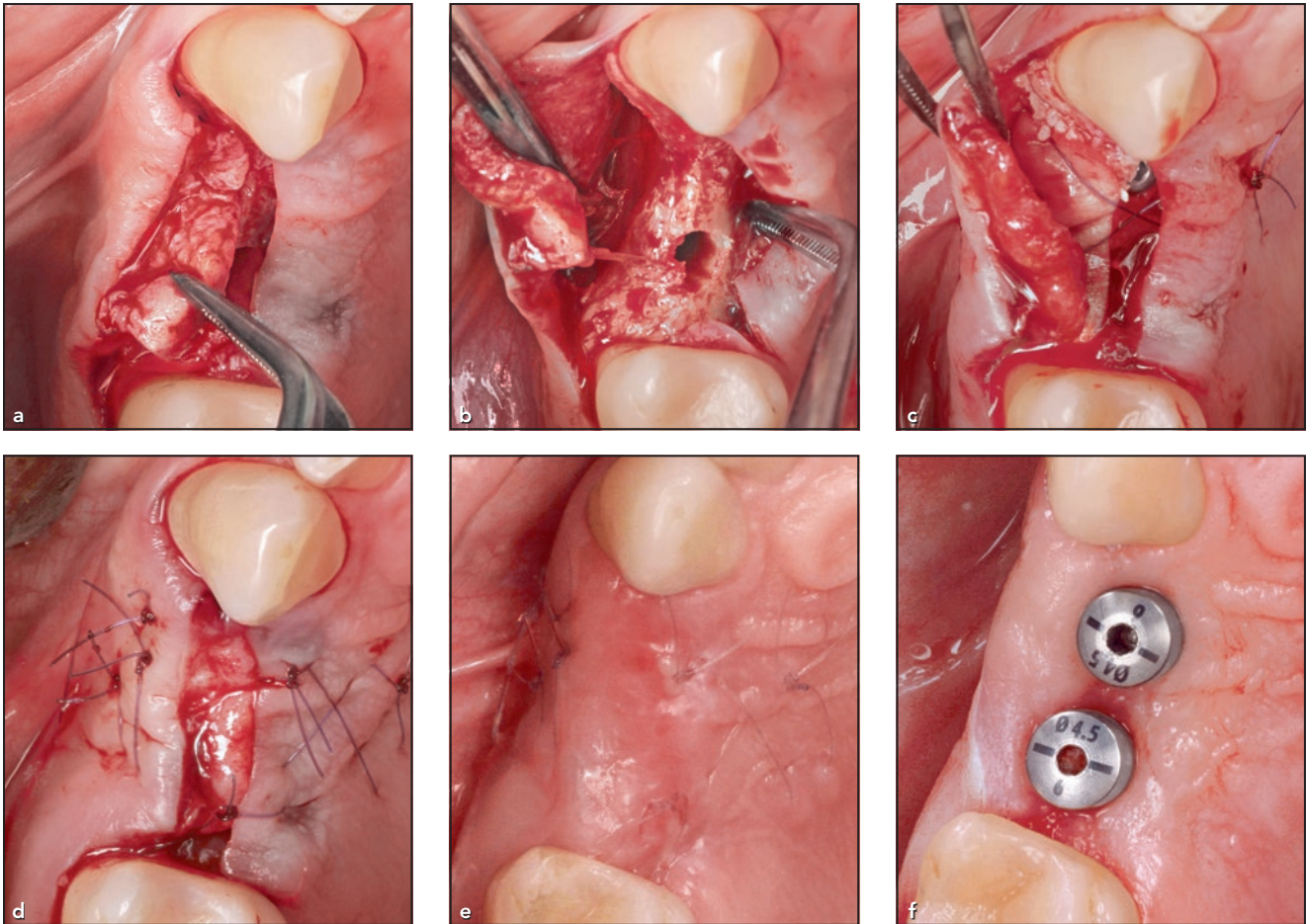


Fig 2 (a) Preparation and elevation of the BSPPF. (b) Ridge exposure and implant site preparation. (c) Horizontal ridge augmentation. (d) Primary wound closure. An area of 3.0 mm of dissected palatal connective tissue is left exposed. (e) Healing 3 weeks after surgery. (f) Ridge appearance 4 weeks after implant uncovering.

approach (Fig 1d). Primary wound closure is performed with deep horizontal mattress sutures (Glycolon 5.0, Resorba; Fig 1e). Continuous or single interrupted sutures may be used additionally if necessary.

Case Reports

BSPPF treatment can be utilized for wound closure after hard ridge augmentation with or without simultaneous implant placement and in combination with the implants provided with healing abutments for

guided soft tissue augmentation. It can further be utilized for wound closure after soft tissue ridge augmentation. Out of 43 sites with BSPPF utilized for wound closure, two cases are presented.

Wound Closure After Implant Placement with Horizontal Ridge Augmentation

After BSPPF preparation (Fig 2a), implant sites were prepared according to the Versah osseodensification protocol with Densah Burs. Two im-

plants (Astra Tech OsseoSpeed TX, Dentsply Sirona) were inserted (Fig 2b). Buccal bone was augmented using the sandwich technique as described by Wang et al.¹³ A resorbable collagen membrane (Bio-Gide, Geistlich) was fixed with resorbable monofilament sutures for guided bone regeneration (Fig 2c). Deep horizontal mattress sutures were utilized for wound closure. Approximately 3.0 mm of the palatal connective tissue was left exposed to heal by secondary intention (Fig 2d). Three weeks after surgery, the implant site displayed good healing

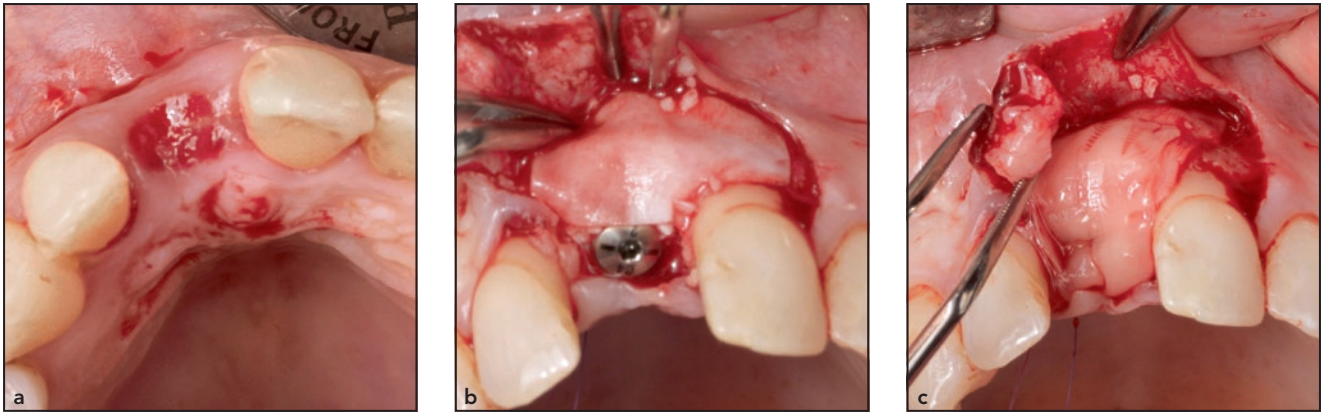
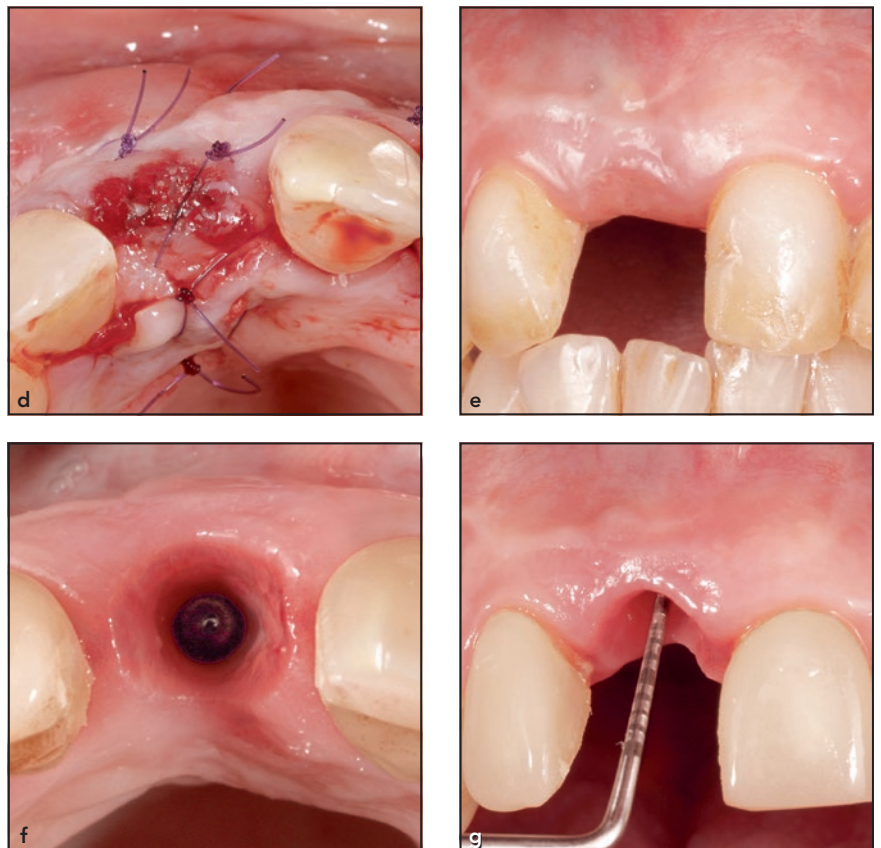


Fig 3 (a) Initial situation. (b) After horizontal ridge augmentation, the implant is provided with a healing abutment 2.0 mm in height. (c) The dissected surface of the BSPPF is visible. (d) Connective tissue (4.0 mm) is left exposed. (e) Facial view of the healed site. (f) Occlusal and (g) facial views after soft tissue maturation. Vertical soft tissue thickness is 5.0 mm.



conditions (Fig 2e). At the second-stage surgery, implants were provided with healing abutments 6.0 mm in height (Fig 2f).

Guided Soft Tissue Augmentation During Implant Placement

Simultaneously with implant insertion, horizontal ridge augmentation was performed in the area of the right central incisor. A BSPPF was prepared as previously described. The implant (Astra Tech Osseo-

Speed TX) was provided with a 2.0-mm-high healing abutment and was let to heal submerged (Figs 3a to 3c). A 3.0-mm-wide area of the palatal connective tissue was left exposed (Fig 3d). After uneventful

healing (Fig 3e), a healing abutment 6 mm in height was placed at the time of implant exposure. Final vertical soft tissue thickness was 5.0 mm (Figs 3f and 3g).

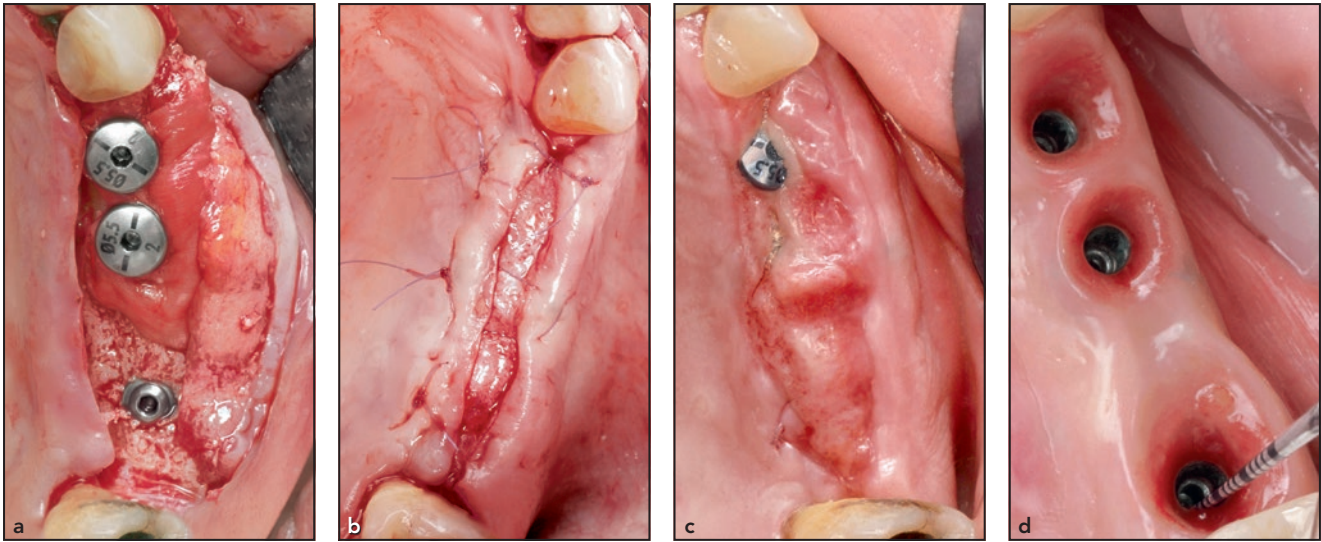


Fig 4 (a) After BSPPF preparation, implants with healing abutments 2.0 mm in height are placed and the ridge is augmented. (b) Horizontal mattress sutures are utilized for the wound closure, leaving 2.0 to 3.0 mm of the palatal connective tissue exposed. (c) Two weeks after surgery, failure of complete coverage is seen. Impressions resulting from the temporary removable denture are visible. (d) Occlusal view after soft tissue shaping with provisional crowns. The measured vertical soft tissue height was 4.0 mm.

Results

The amount of achieved keratinized gingiva and vestibulum depth were evaluated by clinical examination and visual assessment only. In the cases where the BSPPF was combined with guided soft tissue augmentation (15 sites) after tissue maturation and shaping with provisional crowns, the vertical soft tissue dimension was measured utilizing a periodontal probe (15-mm UNC probe, Hu-Friedy) with markings at each millimeter. The soft tissue thickness was measured from the implant shoulder to the midbuccal gingival margin. The average soft tissue thickness was 3.5 mm.

Complications could be observed in 4 out of 15 sites where the BSPPF technique was utilized for guided soft tissue augmentation at the time of implant placement. Healing abutments were exposed prematurely without any signs of

infection of the peri-implant soft tissue. The patient case presented in Fig 4 displayed exposure 2 weeks after implant placement with hard tissue augmentation in combination with guided soft tissue augmentation. This patient was provided with a removable provisional prosthesis (Essix), produced before implant placement and ridge augmentation, being not adequately adapted to the new situation. Figure 4d shows sufficient volume of peri-implant soft tissue despite premature exposure. Wound dehiscence did not occur at the other 39 sites treated with BSPPF for other indications.

Discussion

Current treatment concepts predominantly focus on providing optimized peri-implant soft tissue conditions before the start of the prosthetic phase and insertion of

the final reconstruction.¹⁴ Proper manipulation of peri-implant soft tissue leads to preservation of physiologic conditions in the oral cavity and is prerequisite for long-term success in implant therapy.¹⁵⁻¹⁷ A healthy keratinized peri-implant mucosa serves like an anatomical cuff around the implant collar, thus constituting a functional barrier between the oral environment and dental implants.¹⁸ As shown by the results of a systematic review, implants placed with an initially thicker peri-implant soft tissue reveal less bone resorption in the short term.¹⁶ Peri-implant soft tissue thickness can be enhanced at the time of implant placement by utilizing the BSPPF technique in combination with guided soft tissue augmentation, as described by Salama et al.⁷ A BSPPF can be utilized for primary wound closure after ridge augmentation, with or without implant placement. Since minor to moderate

flap advancement can be achieved, depending on the amount of required bone augmentation and on the width of the palatal tissue, BSP-PF can be applied as a single treatment measure, or as a supplement to a buccal flap repositioning.

For large ridge augmentations, palatal expansion of tissue reduces the need for buccal flap advancement in order to attain primary closure. Thus, it may avoid the need for vestibuloplasty and soft tissue grafts as a secondary procedure.

The most common complication is the exposure of the postsurgical site. In all cases, the premature exposure was visible at the marginal part of the dissected and intentionally exposed connective tissue. A possible explanation is the reduced blood supply in the marginal area of the flap with reduced thickness.

The proposed method is a valid surgical approach because of the favorable risk-benefit ratio. The surgical procedure is not technically demanding, and it is possible to obtain a sufficient sliding position of the palatal tissue for minor to moderate flap advancement (1.0 to 6.0 mm).

Conclusions

Limitations of BSPPF technique include its limitation to the posterior maxilla. Provided there is sufficient palatal soft tissue thickness and shallow rugae palatinae, this technique may also be applied in anterior maxilla. Further, BSPPF should not be extended distal to the first molar because of the potential risk

of great palatal artery damage. Additionally, a minimum 3.0-mm thickness of the palatal soft tissue is required for flap building.

A limitation of this case series presentation is that soft tissue thickness, vestibulum depth, and the amount of keratinized tissue were not measured before and after surgery. In order for accurate evaluation of the results, a prospective study respecting the above-mentioned parameters should be conducted.

Acknowledgments

The authors declare no conflicts of interest.

References

1. Araújo MG, Sukekava F, Wennström JL, Lindhe J. Ridge alterations following implant placement in fresh extraction sockets: An experimental study in the dog. *J Clin Periodontol* 2005;32:645–652.
2. Wang HL, Boyapati L. "PASS" principles for predictable bone regeneration. *Implant Dent* 2006;15:8–17.
3. Sakkas A, Schramm A, Winter K, Wilde F. Risk factors for post-operative complications after procedures for autologous bone augmentation from different donor sites. *J Craniomaxillofac Surg* 2018;46:312–322.
4. Jensen AT, Jensen SS, Worsaae N. Complications related to bone augmentation procedures of localized defects in the alveolar ridge. A retrospective clinical study. *Oral Maxillofac Surg* 2016;20:115–122.
5. Tinti C, Parma-Benfenati S. Coronally positioned palatal sliding flap. *Int J Periodontics Restorative Dent* 1995;15:298–310.
6. Fugazzotto PA. Maintenance of soft tissue closure following guided bone regeneration: Technical considerations and report of 723 cases. *J Periodontol* 1999;70:1085–1097.
7. Salama H, Salama M, Garber D, Adar P. Developing optimal peri-implant papillae within the esthetic zone: Guided soft tissue augmentation. *J Esthet Dent* 1995;7:125–129.
8. Scharf DR, Tarnow DP. Modified roll technique for localized alveolar ridge augmentation. *Int J Periodontics Restorative Dent* 1992;12:415–425.
9. Merli M (ed). Flap extension techniques. In: *Implant Therapy, vol 1: The Integrated Treatment Plan*. Italy: Quintessence, 2012:636–638.
10. Linkevičius T, Puišys A, Linkevičius R, Alkimavičius J. Influence of subcrestal implant placement or use of 2 mm healing abutment to stabilise crestal bone in thin tissue patients [abstract]. *Clin Oral Implants Res* 2018;29:311.
11. Linkevičius T, Apse P, Grybauskas S, Puišys A. The influence of soft tissue thickness on crestal bone changes around implants: A 1-year prospective controlled clinical trial. *Int J Oral Maxillofac Implants* 2009;24:712–719.
12. Reiser GM, Bruno JF, Mahan PE, Larkin LH. The subepithelial connective tissue graft palatal donor site: Anatomic considerations for surgeons. *Int J Periodontics Restorative Dent* 1996;16:130–137.
13. Wang HL, Misch C, Neiva RF. "Sandwich" bone augmentation technique: Rationale and report of pilot cases. *Int J Periodontics Restorative Dent* 2004;24:232–245.
14. Puišys A, Linkevičius T. The influence of mucosal tissue thickening on crestal bone stability around bone-level implants. A prospective controlled clinical trial. *Clin Oral Implants Res* 2015;26:123–129.
15. Linkevičius T, Apse P, Grybauskas S, Puišys A. Reaction of crestal bone around implants depending on mucosal tissue thickness. A 1-year prospective clinical study. *Stomatologija* 2009;11:83–91.
16. Suarez-Lopez Del Amo F, Lin GH, Monje A, Galindo-Moreno P, Wang HL. Influence of soft tissue thickness on peri-implant marginal bone loss: A systematic review and meta-analysis. *J Periodontol* 2016;87:690–699.
17. Zola MB. Methods of designing, elevating, and suturing the intraoral flap. *Oral Implantol* 1972;3:5–18.
18. Boynueğri D, Nemli SK, Kasko YA. Significance of keratinized mucosa around dental implants: A prospective comparative study. *Clin Oral Implants Res* 2013;24:928–933.